



COMMON SKIN LESIONS IN OLDER ADULTS

SARAH W. MATTHEWS, DNP,
ARNP, FNP-BC

KAISER PERMANENTE
DERMATOLOGY

UW SCHOOL OF NURSING

Agenda

Skin Changes Related
to Aging

Benign Skin Lesions

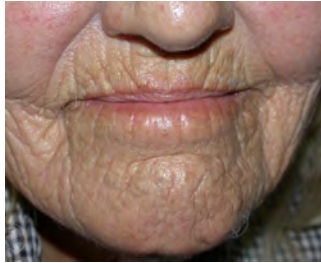Pre-Malignant &
Malignant Skin Lesions

External Influences on Skin Aging



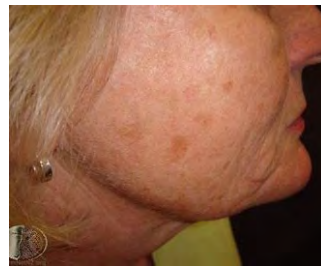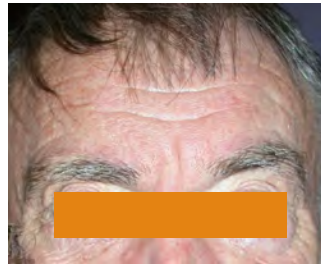Examples of UV Skin Damage

Wrinkling	Solar Lentigines	Guttate Hypomelanosis
Telangiectasia	Thin Skin	Solar Purpura
Venous Lakes	Comedo	Altered Aging of Skin Cells (Drying)



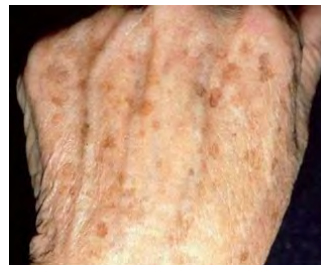Wrinkling

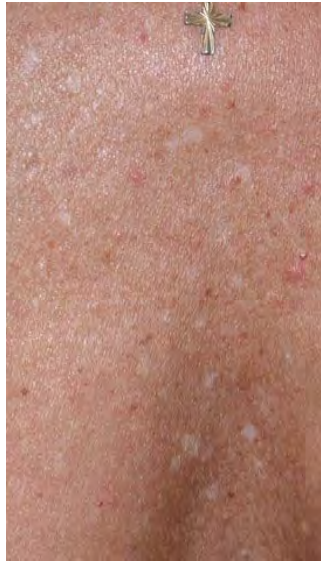- Caused by facial expressions but also overexposure to the sun or smoking



Solar Lentigines

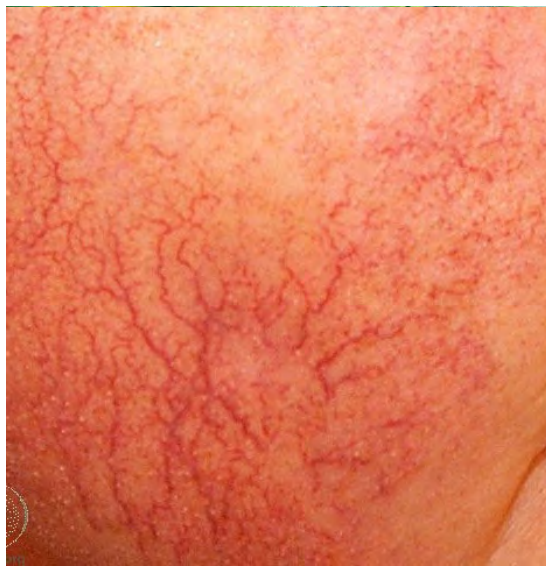- AKA - liver spots
- Flat, brown lesions on sun-exposed skin.
- Most commonly on face, forearms, backs of hands
- Caused by excessive UV light exposure.
- More than half of all people over age 64 will have a least one *solar lentigo*, most have more
- Consider possibility of lentigo maligna – single lesions different from others deserve a biopsy





Guttate Hypomelanosis

- White spots caused by ultraviolet damage from too much sun
- Ultraviolet rays can permanently damage the skin's ability to produce pigment

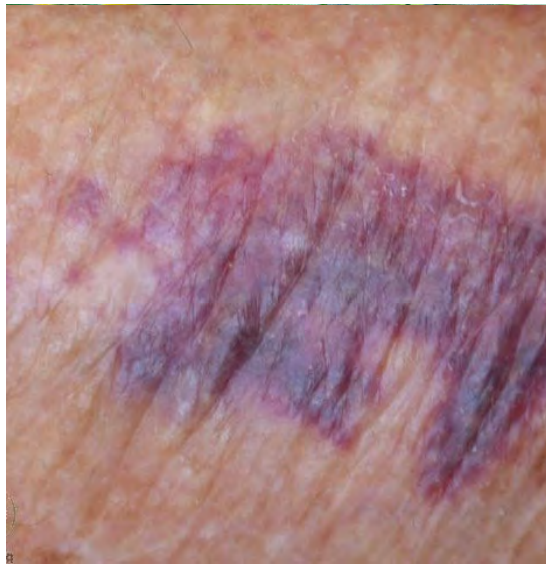
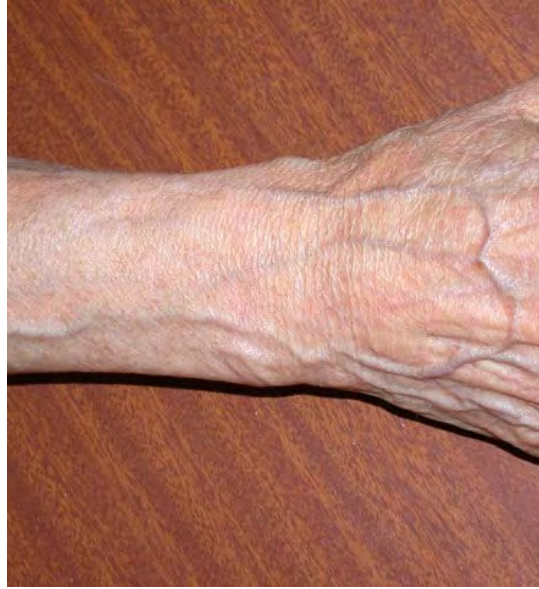
Telangiectasia

- Enlarged blood vessels due to damage to collagen in vessel walls
- Caused by the sun's ultraviolet rays
- Other common cause is rosacea

Thin Skin

- Sun damage can lead to the thinning of the skin
- Thinned skin susceptible to injuries such as easy tearing or bruising

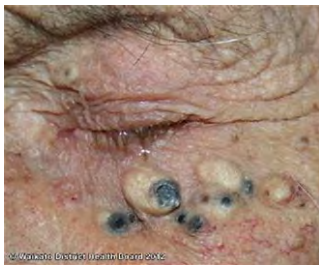
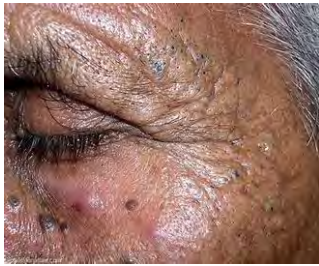
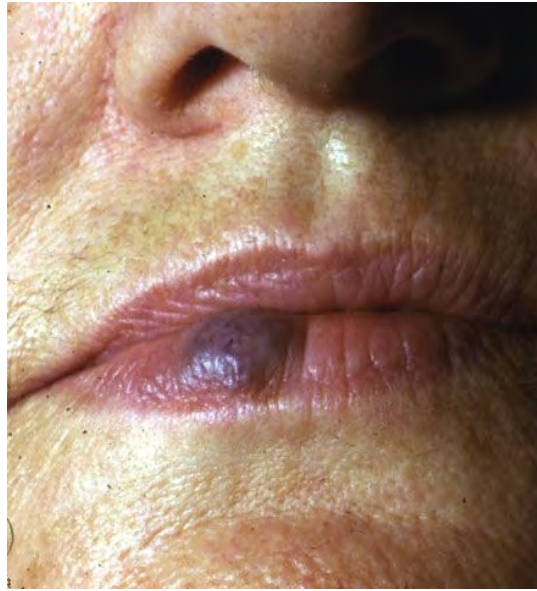Solar Purpura

- AKA - senile purpura
- Sun damages supporting collagen around blood vessels which can lead to a form of bruising associated with skin that is thin and inelastic
- Typically reported as marks occurring with minimal trauma
- ASA and other blood thinners also contribute

Venous Lakes

- Sun damage causes veins that are close to the surface of the skin to enlarge
- This can lead to a “lake” or pooling of the blood
- Benign but if not sure refer for possible biopsy

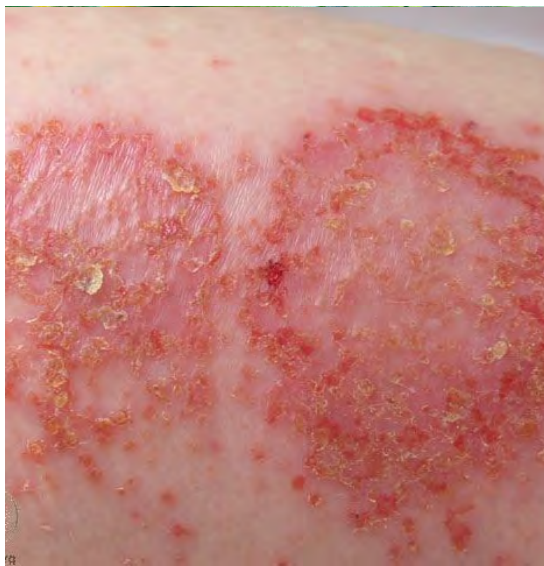
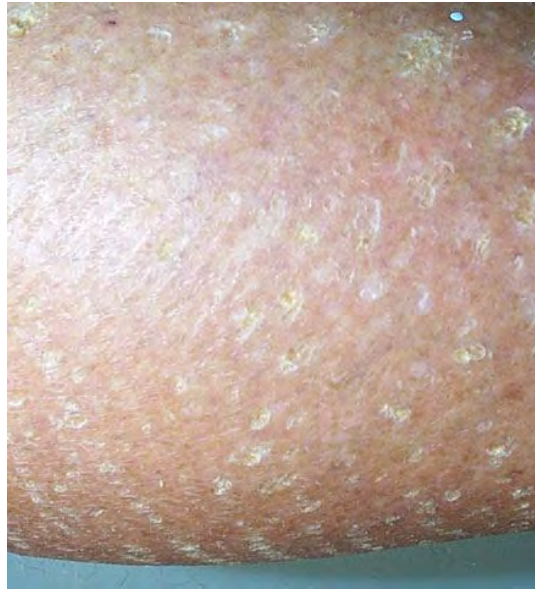
Comedo

- Chronic blackheads caused by sun damage to hair follicles
- Mild in most cases and not treated
- Treatment options - tretinoin cream and extraction

Drying or Xerosis

- Xerosis more common in seniors due to sun causing abnormal aging & adhesion of skin cells → rough, dry, scaling skin
- Diminished sweat & oil gland function also play a role



Xerosis related Dermatitis

- *Xerosis* - most common skin abnormality in seniors
- Most frequent cause of itching
- Scratching can lead to inflamed skin (*dermatitis*)

Prevention of Skin Aging

“An ounce of prevention is worth a pound of cure.”



- Minimize sun exposure (avoidance, appropriate clothing, sunglasses & sunscreen \geq 30 SPF) – consider vitamin D supplement



- Avoid the use of tobacco products



- Eat a healthy diet, stay hydrated & exercise regularly

Skin Lesions

Benign Skin Growths

Skin Cancer

Benign Skin Growths

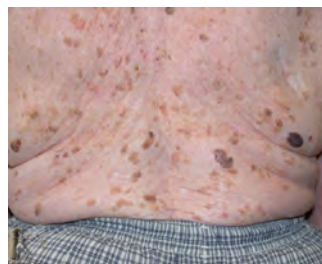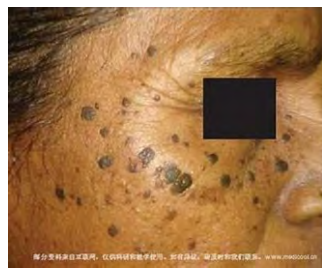Seborrheic
Keratoses

Cherry Angiomas

Nevi

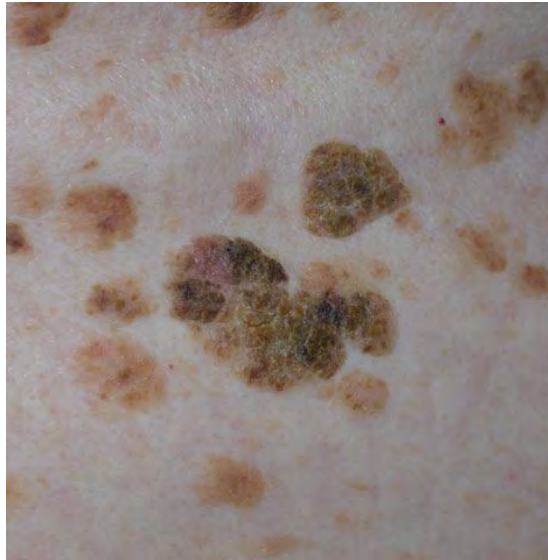Skin Tags

Sebaceous
Hyperplasia



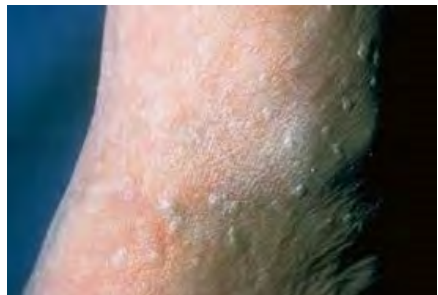Seborrheic Keratosis

- Most common benign growths of the skin
- 88% of people over 64 have them
- Typically begin to appear in middle-age or later and can occur anywhere except palms and soles
- Tend to be tan, gray, brown or black, warty or waxy and appear to be “stuck on”
- Any new or changing lesions need to be evaluated to be sure they are not skin cancers
- If growing quickly, bleeding, hurting, black appearance – consider biopsy (could be melanoma masquerading as SK)



Seborrheic Keratoses

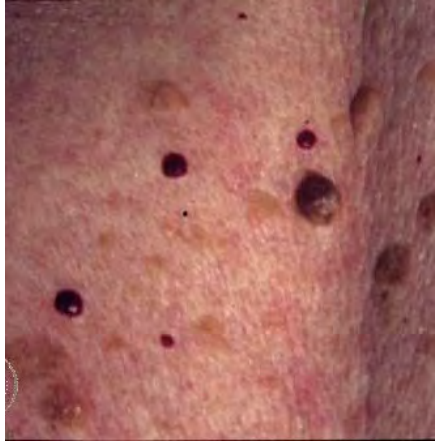
- Not usually treated (benign).
- Treatment of non-symptomatic lesions is considered elective (not covered by insurance or Medicare)
- If inflamed due to trauma, they can be treated with liquid nitrogen (can scar or recur)
- Can smooth with moisturizers that peel slightly (12% ammonium lactate)



Stucco Keratoses

- Variant of seborrheic keratoses
- 1-4 mm gray to white scaly bumps, usually on arms and lower legs
- Can be treated with special moisturizers with lactic acid (alpha hydroxy) to smooth and soften
- 12% Lactic Acid Lotion/Cream, Amlactin, Lac-Hydrin

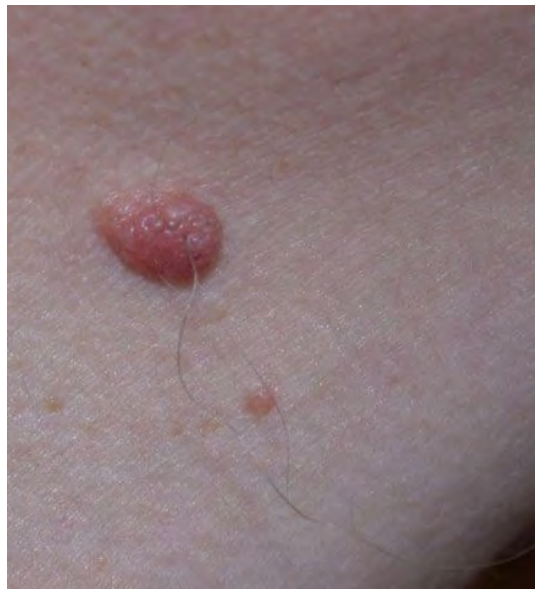Cherry Angiomas

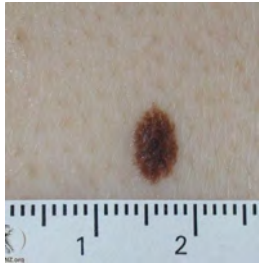
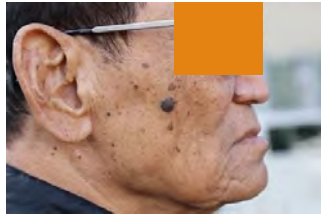
- Most common benign vascular lesions, first seen in 30s/40s, increase in number over time
- Not unusual for seniors to have 50-100 on their trunk
- Round to oval, bright red or purple, dome-shaped papules
- Usually not treated but can be removed by cauterization, surgery or laser

Nevi (Moles)

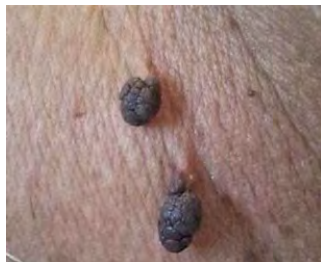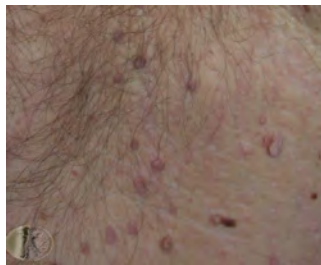
- Prevalence is related to age, race and perhaps genetic and environmental factors
- Very few are present in childhood
- Peak in the 3rd decade then they tend to disappear with increasing age
- Seen more in Caucasians but seen in all races





Nevi

- Increased number of nevi occurs in some families
- Some evidence that individuals in sunny climates have more
- Most are benign but melanoma can arise from a long standing-nevus (about 1/3 of the time)
- Increased number of nevi (>50) marks increased melanoma risk

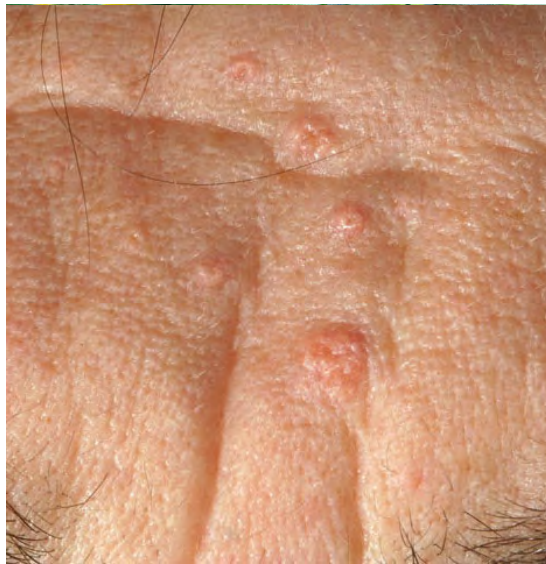
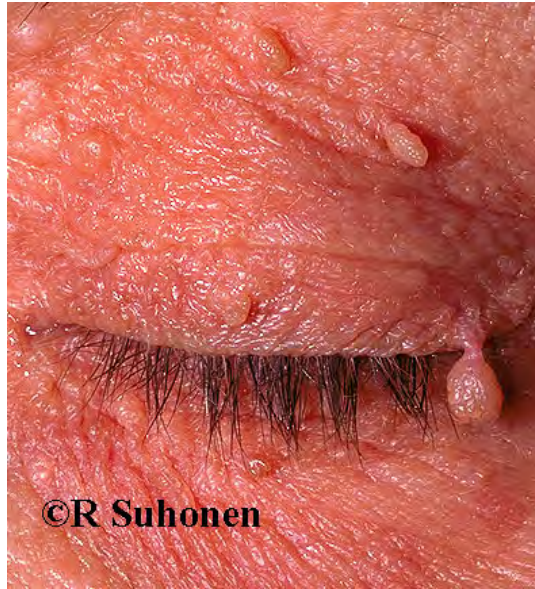
Skin tags

- Benign, soft, skin-colored to tan, pedunculated growths, predominately on the neck, armpits, and groin
- Very common, incidence increases with age
- 50% of all individuals have them

Skin tags

- Usually not treated (cosmetic) unless irritated
- If warranted they can be easily removed by clipping them off, cautery or freezing
- Clipping can lead to significant bleeding
- Refer eyelid skin tags since removal must be done very carefully given thinness of skin
- Will most likely be out of pocket expense

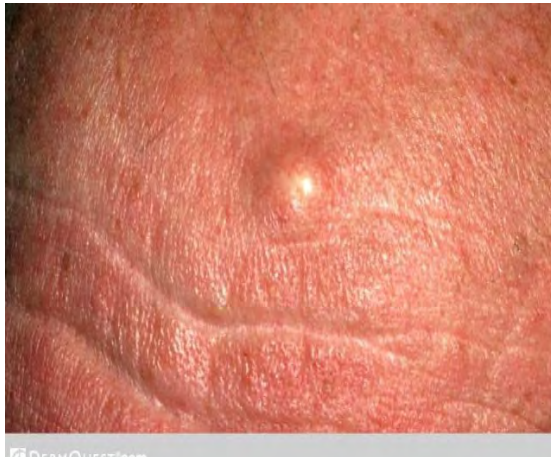

Sebaceous Hyperplasia

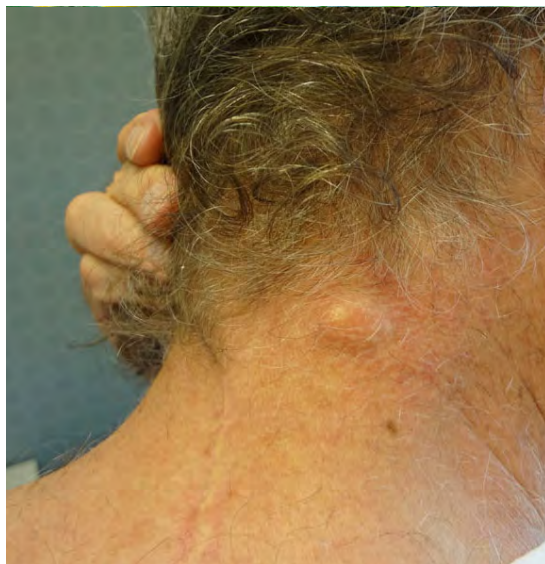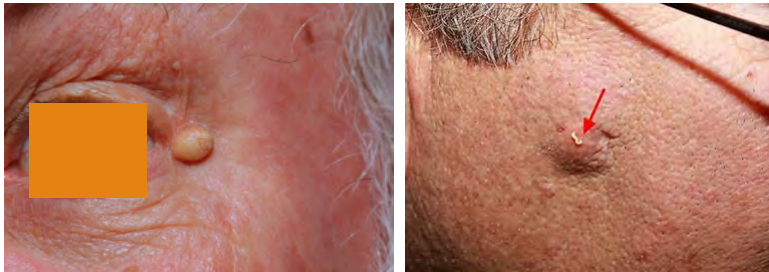- Benign enlargement of sebaceous (oil) gland
- Yellowish "cobblestone" growths, usually on central or upper face, sometimes on the upper trunk
- Biopsy sometimes indicated to rule out skin cancer
- Usually not treated (difficult to treat since they are part of the gland)

Epidermal Cysts

- Most often on face, neck, and trunk but can be anywhere
- Result from plugging of the follicular orifice, often in association with acne
- One of most common benign skin tumors



Epidermal Cysts



Epidermal cysts

- Compressible, but not fluctuant, smooth, mobile, 0.5-3 cm cystic mass
- Surface is usually smooth and shiny from the upward pressure
- Pasty contents are formed mostly of macerated keratin which is cheese-like and malodorous

Epidermal Cysts

Diagnosis based on history and clinical exam

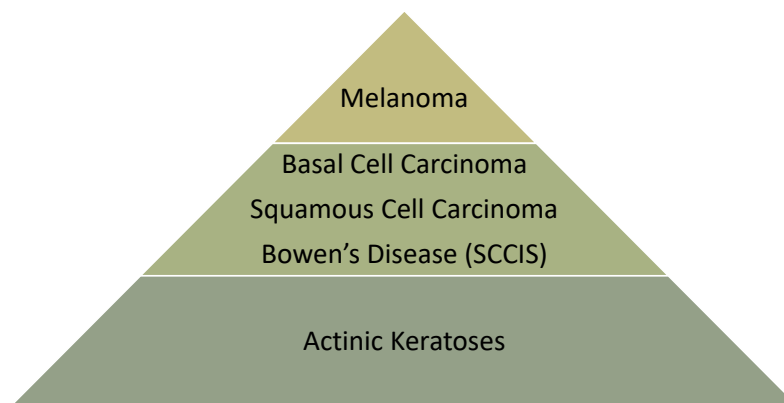
History – length of time, growth, pain, redness, warmth, drainage, fever, malaise

Inflammation due to rupture inducing rigorous foreign body inflammatory response (sudden onset of redness, pain, swelling, and local heat)

Treatment

- Monitor vs. excision
- Surgical excision is curative but complete cyst must be removed
- Insurance may not cover removal unless > 2 cm
- Cannot excise while inflamed - if inflamed, consider I&D and possibly antibiotics

Skin Cancers & Pre-cursors



Lesion History



Length of time



Rapid growth



Change in color



Bleeding



Itching



Pain

Other History

Previous treatments for AKs or skin cancer

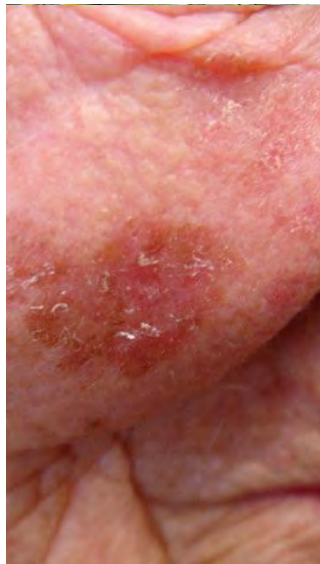UV exposure

- Severe sunburns
- Tanning booth
- Sunscreen
- Radiation

Family history

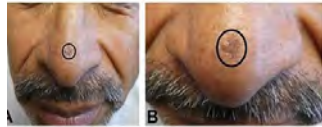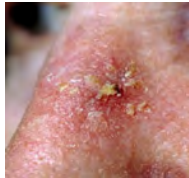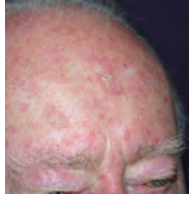- 1 in 10 pts with melanoma has FH
- 50% > risk with 1st degree relative
- P53, BRAf and other gene mutations associated with familial melanoma
- People with atypical moles and FH of melanoma at greatest risk

Actinic Keratoses



Actinic Keratoses

- In situ dysplasia due to sun damage
- 80% of AKs occur on the head, neck, dorsal hands, forearms
- Tan-red, keratotic, flat or slightly elevated, can be shiny, sometimes tender or itchy
- Often easier to feel than see, 3-10 mm typically
- If >6 mm or palpable dermal component consider biopsy to confirm diagnosis, especially if not responding to LN2 or topical therapy



Actinic Keratoses

- Risk factors - prior history of AKs, increased age, male gender
- 1-4% of AKs estimated to become SCC
- Lifetime risk SCC in an individual with AKs is estimated to be 6-10%
- As many as 25% will resolve spontaneously (seems to occur with strict sun protection)

AK Treatment Options

Destructive therapy

- Liquid nitrogen - primary approach to isolated lesions

Field-directed therapies

- Indicated for areas with multiple AKs, subclinical lesions that are not detected by visual inspection or palpation
- Topical medications (e.g., 5-fluorouracil, imiquimod, chemical peels, photodynamic therapy [PDT])
- Usually, field treatment is done by dermatology providers

Liquid nitrogen (LN2)

Studies

- Efficacy of LN2 was demonstrated in study of 70 patients with 1018 treated AKs. Cure rate of 99% reported after one year. Most lesions were thin, not on arms/hands, aggressive therapy (thaw times of 20-45 seconds)
- Subsequent prospective study included 90 patients with 421 AKs, the overall complete response rate (defined as 100 percent lesion clearance) to LN2 was 67%

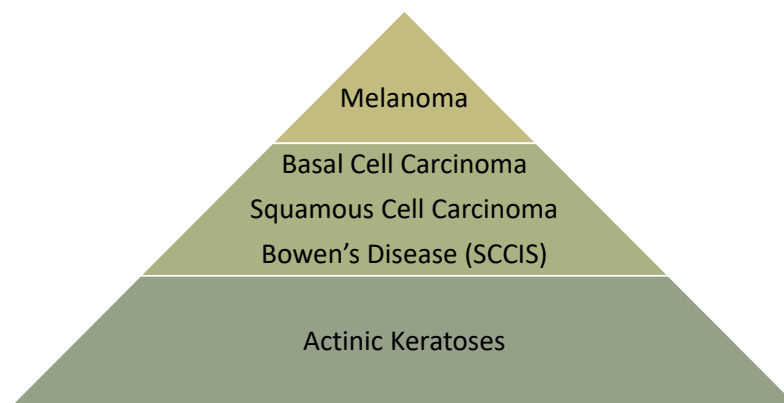
Response rate varied with freeze time (time lapse from ice ball formation to beginning of thawing) - 39% for 5 sec, 83% for 20 sec

Although hypertrophic AKs can be effectively treated with LN2, thick lesions may respond less well than thin lesions

Effective treatment - 2 cycles of 10 sec

Judgment call - thickness of AK and location (face heals faster but cosmetically sensitive, arms scar easily but may require more aggressive treatment)

Skin Cancers



Risk Factors for Skin Cancers

Sunlight – chronic bursts of sun (sunny vacations)

Tanning beds (associated with melanoma)

Radiation (for treatment of other cancers)

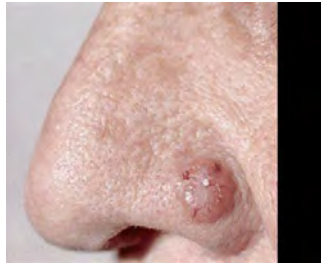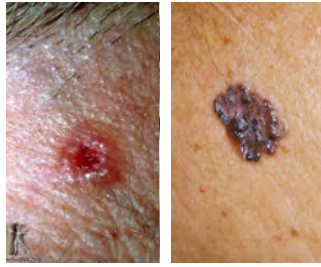
Wart virus/human papilloma virus (seen mostly in transplant patients and genital SCC)

Cigarette smoking (two-fold increase in risk for SCC)

Immunosuppression due to organ transplant, AIDS, or medications causing immunosuppression

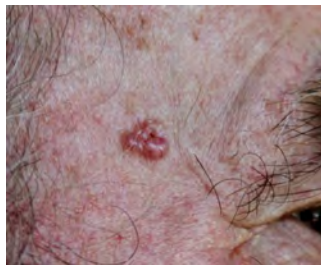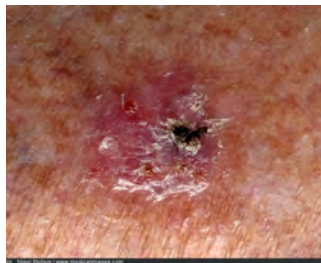Chronic, non-healing or inflammatory wounds

Basal Cell Carcinoma



Basal Cell Carcinoma

- Most common skin cancer in Caucasians
- African Americans and Asian/Pacific Islanders at lowest risk but still at risk
- Rates increase with age
- Incidence increasing in people under 40 years
- Especially women (partially due to tanning beds increasing risk)
- Median age ~69 years old
- 40% will have another within 5 years



Basal Cell Carcinoma

- Mortality rates are low but can be locally invasive and destructive
- Low metastatic potential
- Locally invasive and destructive of skin, muscle, cartilage
- Disfiguring if not treated

BCC Diagnosis

About 70 percent of BCCs present on the face and head

Biopsies used to confirm diagnosis & determine histologic subtype

Once the diagnosis is established, appropriate treatment offers a high probability of cure, although the patient remains at increased risk for additional skin malignancies

Ultraviolet link to BCC



BCC development appears to relate more directly to intermittent sun exposure (sunny vacations) and over exposure to the sun (i.e. sunburns), especially in childhood and adolescence



Exposure pattern resembles that which produces melanoma



Incidence is increasing worldwide

High Risk BCC

Infiltrating

Morpheaform

Micronodular

Basosquamous

Sclerosing

Desmoplastic

Perineural invasion

BCC Treatment

Electrodessication & curettage (ED&C)

- BCCs in low-risk sites (neck, trunk, and extremities) had a 3 % recurrence rate
- < 10 mm in diameter and located on the scalp, forehead, preauricular and postauricular areas, or the malar areas had a 5 % recurrence rate
- > 10 mm had a 23 % recurrence rate
- < 6 mm in diameter in high-risk sites (nose, paranasal, nasolabial groove, ear, chin, mandibular, perioral, periocular areas) had a 5% recurrence rate, while tumors > 6 mm had a recurrence rate of 18 %

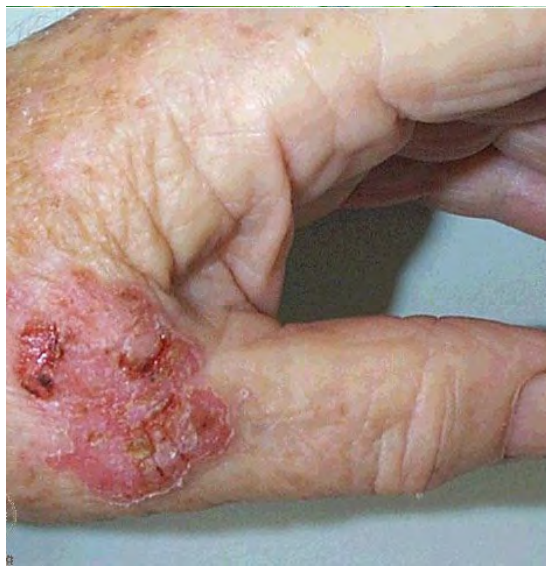Surgical excision

- Surgical excisions of truncal, extremity and small facial BCCs with 4-5 mm margins is associated with 5-year cure rate of 95%

Mohs surgery

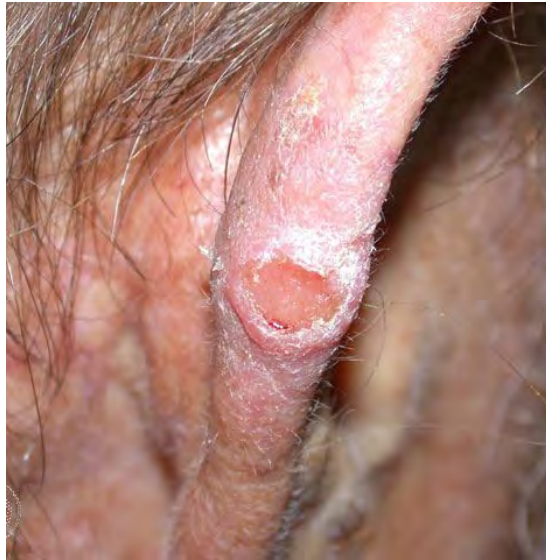- Optimizes control of the tumor margins while optimizing cosmetic result.
- T-zone of face, ears, scalp (large lesions)

Squamous Cell Carcinoma



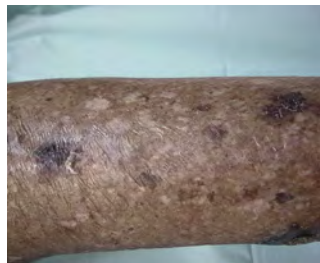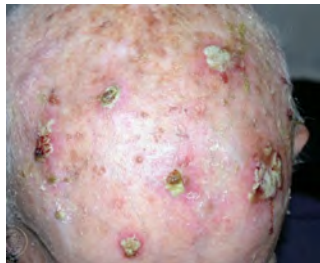Bowen's Disease

- Superficial form of *squamous cell carcinoma (SCC)*
- Can develop from an AK
- Bowen's Disease enlarge slowly over years and seldom progress to invasive SCC
- Usually treated with topical chemotherapy or surgical removal



Squamous Cell Carcinoma

- Second most common skin cancer
- Median age 75 years old
- Majority of deaths due to SCCs arising on the ear
- Clinical findings depend on type of lesion and location - erythematous papules, plaques, or nodules
- Hyperkeratosis, ulceration, or hyperpigmentation also seen



Squamous Cell Carcinoma

- SCC can metastasize
- Mortality rate significantly higher for SCCs than BCCs
- Rate of both NMSCs higher in men
- Occurs on head, neck, trunk, extremities, oral mucosa, periungual skin, and anogenital areas
- Sun-exposed sites are the most common locations in fair-skinned people
- Involvement of other areas is more common in people with dark skin
- High risk lesions are ear, lip, genitalia, and scalp

Squamous Cell Carcinoma

- Can develop in sites of chronic wounds, chronic inflammation, or scarring and can be more aggressive
- Non-healing ulcers or nodules in these sites can be a manifestation of SCC
- Biopsy is necessary to confirm the diagnosis
- For lesions clinically suspected to be invasive, a shave, punch, or excisional biopsy that extends at least into the mid-reticular dermis is preferred

SCC Treatment

Cured with local therapy in over 90 percent of cases

Higher potential for local recurrence, regional or distant metastases than BCC

Delayed diagnosis or inadequate treatment can result in increased morbidity or death

Major treatment options for SCC with low-risk for recurrence and metastasis are surgical excision, cryotherapy, electrosurgery, and radiation therapy

Treatment - depends upon the experience of the clinician, the expected cure rate, cosmetic factors, and patient preference

Topical chemotherapy with topical 5-fluorouracil (5-FU) or imiquimod and PDT are options for Bowen's disease

Radiation therapy is an additional option for the management of primary cutaneous SCCs in older patients and those who are not surgical candidates

SCC Follow-up

After a primary SCC, the estimated risk for any second NMSC is about 50% at 5 years

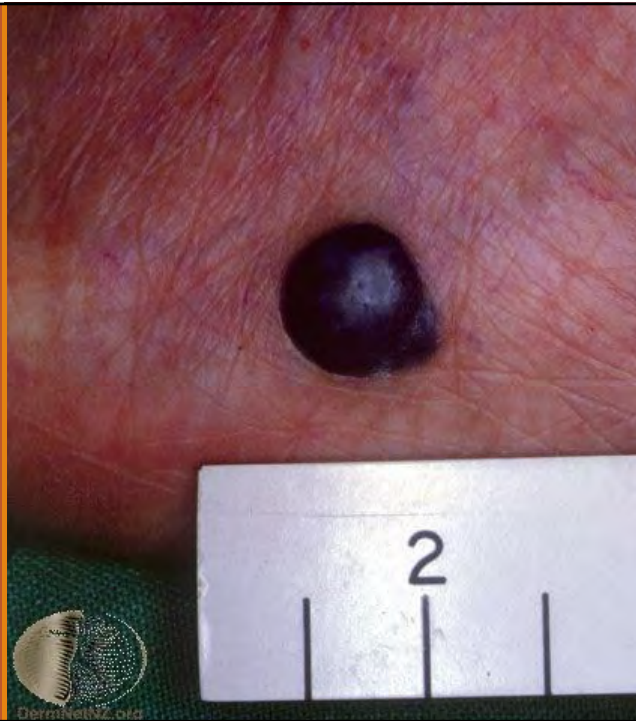Careful follow-up is required to evaluate for evidence of local recurrence, regional or distant metastasis, and treatment-related complications

Recommend skin checks every 3-6 months in first 2 years then yearly

Melanoma

Melanoma - nodular

- Tumor arising from melanocytes (pigment making cells)
- Incidence and death rates have been rising in recent decades
- Increasing faster than any other potentially preventable cancer in the US
- Among the most common types of cancer in young adults
- Most common sites – back (men) & lower leg (women)



Melanoma History & Exam

Risk factors

- Presence of a high number of common nevi
- One or more atypical nevi
- Light skin phenotype
- Excessive sun exposure
- History of sunburns
- Moles on palms, soles and mouth

Important question

- Do you have any concerns about a particular lesion (or does your spouse/significant other have concerns) or have you noticed a ***new mole or a change in a preexisting mole?***

Melanoma History & Exam



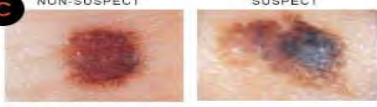


Personal or family history (especially first-degree relatives) of melanoma or other skin cancers

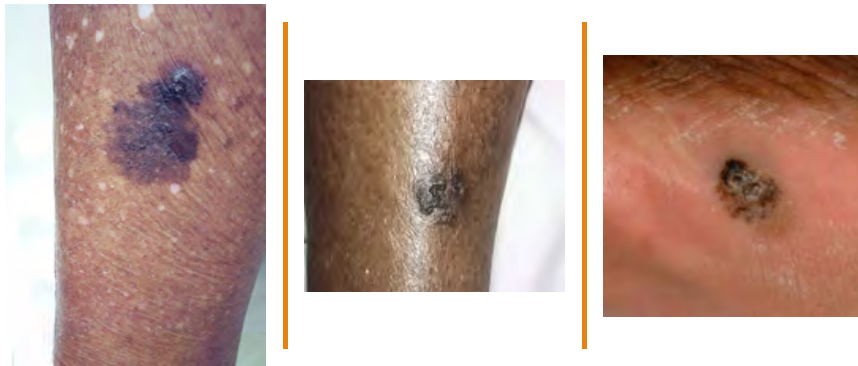Total body skin examination

- Full skin exam (FSE) for melanoma requires a source of bright light and, ideally, a magnifying lens.
- FSE could be integrated into routine physical exams by adequately trained primary care providers.

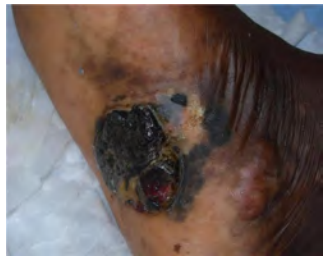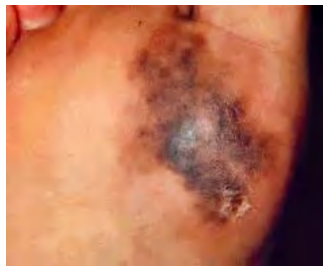Identify lesions using ABCDE and “ugly duckling”

The ABCDE Method
The best way to detect melanoma is to regularly check and take note of all the spots on your body. See a dermatologist immediately if you notice any of these warning signs:

<p>A NON-SUSPECT SUSPECT</p>  <p>ASYMMETRY One side is not the same or symmetrical to the other</p>	<p>B NON-SUSPECT SUSPECT</p>  <p>BORDER Irregular or poorly defined border</p>	<p>C NON-SUSPECT SUSPECT</p>  <p>COLOR Features several shades and colors, from light brown to black</p>
<p>D NON-SUSPECT SUSPECT</p>  <p>DIAMETER Usually greater than 6mm in diameter</p>	<p>E NON-SUSPECT SUSPECT</p>  <p>EVOLVING Evolving in size, color or thickness</p>	

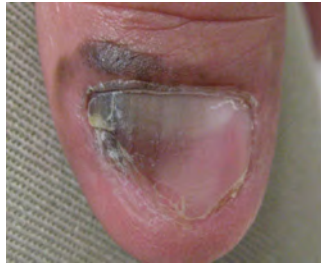
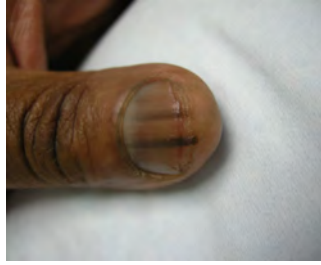

Melanoma: Seen in all skin types



Acral Melanoma

- Average age at diagnosis 60-70 years
- Most common subtype in people with darker skins and is rare in people with lighter skin types
- Palms, soles, under the nails and in the oral mucosa
- Non-hair-bearing surfaces of the body, which have not necessarily been exposed to sunlight
- Found on mucous membranes
- Most common form of melanoma diagnosed amongst Asian and sub-Saharan African ethnic groups



Acral Melanoma

- Nail matrix melanoma - extension of pigment onto skin is key indicator
- Early detection and appropriate excision of the tumor leads to a cure rate of over 90% in thin melanomas (<1 mm thick)
- Acral lesions high risk and should be referred urgently

Melanoma Screening

- Based on risk
 - High - multiple atypical nevi &/or history suggesting a familial melanoma syndrome
 - Moderately high - white men over 50 years, individuals with a history of significant sunburn or multiple moles
- High risk - regular FSE by clinicians with skin expertise, skin self-examination, and sun protection
- Autosomal dominantly inherited mutations in melanoma susceptibility genes are responsible for only a small proportion of cutaneous melanomas - role of genetic screening should be limited to research
- Without identified increased risk - USPSTF recommends clinicians remain vigilant for any suspicious lesions identified during a routine or sick visit (opportunistic case finding) and make appropriate referrals

Summary

- Incidence of melanoma increasing faster than any other potentially preventable cancer in US
- Mortality rate among white men over age 65, who comprise 36 percent of all deaths, more than doubled over the past 30 years
- Risk factors for developing melanoma are both environmental and genetic
- Majority initially detected by patients (or spouses)
- Highest yield for screening is in men ≥ 50 yo
- Melanomas detected in men during a routine clinician exam are thinner than those detected by the patient or his partner
- Poorer survival for men with melanoma, compared to women, may relate both to tumor biology and gender differences in skin awareness, self-examination, and care-seeking practices



Thank
you!
